

## Characterisation of cytotrophoblastic-like cells present in subinvolutioned placental sites of the bitch

P.E. Fernández<sup>1</sup>, E.L. Portiansky<sup>1</sup>, C.G. Barbeito<sup>1,2</sup> and E.J. Gimeno<sup>1</sup>

<sup>1</sup>Institute of Pathology "Prof. Dr. Bernardo Epstein" and

<sup>2</sup>Department of Histology and Embryology, School of Veterinary Sciences, National University of La Plata, La Plata, Argentina

**Summary.** This paper describes an approach to study the cells present in the subinvolution of placental sites (SIPS), a pathological post partum condition of the bitch that causes persistent hemorrhage of the genital tract. The expression of intermediate filament proteins was examined to determine the fetal or maternal origin of the cytotrophoblastic-like cells found in this entity. Lectin binding on tissue sections were also studied to characterise cellular glycoconjugates. Image processing and morphometrical analysis of the histological images were done. The results revealed that the cells observed in bitches with SIPS expressed pancytokeratins but neither vimentin nor desmin, in coincidence with normal cytotrophoblasts. The lectin binding pattern of both types of cells was similar, with the only exception of *Arachis hypogaea* agglutinin (PNA) and *Triticum vulgaris* agglutinin (WGA). These observations, in addition to the non statistically significant differences between morphometrical characteristics of cytotrophoblastic and cytotrophoblastic-like cells in SIPS, might suggest the fetal origin of the latter cells which could play a role in the pathogenesis of this entity.

**Key words:** Subinvolution of placental sites, Trophoblastic cells, Intermediate filaments, Immunohistochemistry, Lectins, Image analysis

### Introduction

The subinvolution of placental sites (SIPS) is one of the unusual pathological post partum conditions of the bitch (Burke, 1977; Al Bassam et al., 1981). This entity might represent a delay in the normal process of placental degeneration and endometrial regeneration (Schall et al., 1971). This alteration is associated with a persistent vulvar serohemorrhagic discharge of variable intensity beyond 6 to 12 weeks postpartum (Al Bassam et al., 1981; Castellano et al., 1982). It occurs mostly in

up to 3-year-old bitches and has been reported in many breeds of dogs.

The histological appearance of SIPS is characterised by the presence of dilated endometrial glands and variable areas of hemorrhage, with necrosis and collagen masses. Typical big and round cells, approximately 50-55  $\mu$ m, appeared in the connective tissue between the glands of the endometrium. Its trophoblastic or decidual origin has been a matter of controversy. Similar cells have been described trespassing blood vessels, except in the endothelium, forming syncytial masses and reaching the myometrium and its blood vessels. Due to the fact that some authors consider these cells as trophoblastic, rejecting the possible decidual origin (Al Bassam et al., 1981; Castellano et al., 1982), it is still necessary to clarify the lineage of the cells.

In normal placentation, cytotrophoblastic cells are responsible for the invasion of the endometrium for a successful implantation with the help of proteolytic enzymes (Strickland and Richards, 1992). The presence of cyto-trophoblastic-like cells, which for unknown reasons did not regress or degenerate but continued to invade the deep glandular layer or even the myometrium, could account for the characteristic hemorrhage present in SIPS. This hemorrhage is considered to be a consequence of an occlusion failure in the vessels in the exposed placental bed, damaged by the cytotrophoblastic-like cells (Al Bassam et al., 1981; Castellano et al., 1982).

Intermediate filaments (IF) are a group of cytoskeletal differentiation-related proteins detected in virtually all eukaryotic cells. Most mesenchymal cells contain vimentin as the main IF-forming protein. On the contrary, epithelial cells have a complicated IF system consisting of cytokeratins (Anderton, 1981; Ramaekers et al., 1986; Alberts et al., 1994).

Lectins, plant-derived proteins which bind specifically but non-immunologically to saccharides, have been used to define the types and distribution of glycoconjugates on normal embryonic and adult cells (Laitinen et al., 1987). They have also been applied to study alterations in cell growth and differentiation in metaplastic and neoplastic conditions (Hsu and Ree,

Offprint requests to: Dr. Patricia E. Fernández, Institute of Pathology, School of Veterinary Sciences, P.O. Box 296, (1900) La Plata, Argentina

1983).

The purpose of the present study was to characterise cytotrophoblastic-like cells present in SIPS, examining the expression of intermediate filament proteins for a better understanding of the pathogenesis of this entity. Through the demonstration of lectin binding on tissue sections, we aimed to study the carbohydrate moieties on the cell surfaces and cytoplasm of cytotrophoblastic-like cells in SIPS.

## Materials and methods

### Tissue samples

Six abnormal involuted uterine horns were examined 6 weeks postpartum. Normal uterine horns, obtained by hysterectomy after 55 days of pregnancy, were used as control samples.

Tissues were fixed in neutral 10% formaldehyde, dehydrated in graded alcohols, and embedded in paraffin. Representative 5 µm sections were stained with haematoxylin and eosin for histopathological diagnosis. The PAS technique was used to detect deposition of glycogen and the Van Gieson's technique to detect collagen tissue.

Paraffin-embedded sections mounted on slides coated with Poly-L-lysine (Sigma Diagnostics, St. Louis, MO, USA) were deparaffinized with xylene, incubated with 0.03% methanolic hydrogen peroxide for 30 minutes at room temperature to inhibit endogenous peroxidase activity, passed through graded alcohols, and rinsed three times in deionized water and phosphate-buffered saline.

### Immunohistochemical staining

The following commercial antibodies were used: polyclonal rabbit anti-cow pancytokeratins (1:300), monoclonal anti-swine desmin clone DE-R-11 (1:100) and monoclonal anti swine vimentin clone V9 (pre-diluted) (Dako Lab, Inc, Ca, USA). The ABC method was applied according to the manufacturer's instructions (Vector Laboratories Inc, Ca, USA). The horseradish peroxidase was activated by incubation during 4-10 minutes with a buffered Tris-HCl solution (0.05M,

pH 7.6) containing 0.02% 3,3'-diamino-benzidine tetrahydrochloride (DAB) and 0.05% H<sub>2</sub>O<sub>2</sub>.

Positively-stained cells were demonstrated by the dark golden brown DAB-H<sub>2</sub>O<sub>2</sub> reaction product.

### Lectin histochemical analysis

Lectin histochemistry was conducted as previously described (Gimeno et al., 1995). Paraffin sections were deparaffinized with xylene and endogenous peroxidase was quenched. They were then hydrated, washed in phosphate-buffered saline, and incubated with biotinylated lectins for 1 hour, followed by incubation using the avidin-biotin-complex (ABC) technique (Vector Laboratories Inc, CA, USA). The horseradish peroxidase was activated as described in the previous section. All the preparations were counterstained with Meyer's haematoxylin.

Table 1 lists the seven lectins (Vector Laboratories Inc, USA) used in this study as well as their acronyms, their concentration and their major sugar specificities (Goldstein and Hayes, 1978).

### Image processing and analysis

Histological images were captured from a microscope (Olympus BX50 system microscope, Tokyo, Japan) with an objective magnification of x40, through a video camera (Sony DXC 151A CCD color video camera, Tokyo, Japan) attached and digitized in a 24-bits true color TIFF format (PC Pentium 120 MHz, 32Mb RAM, SNAPplus desktop video adapter [Cardinal Technologies, Inc., Lancaster, PA, USA], software: Image-Pro Plus for Windows v3.0 [Media Cybernetics, Silver Spring, MA, USA]). The grid matrix of each image had a yield of 0.32 µm/pixel. The background correction operation was performed on each image in order to meaningfully compare the optical density (OD) of the different slides. To separate the immunostain (brown stain) from the hematoxylin stain (blue stain) the cube based method of the Color Segmentation operation was applied. The brownish stain was selected with a sensitivity of 4 (maximum 5). A mask was then applied in order to make the separation of colours permanent. The images were then transformed to an 8 bit gray scale

**Table 1.** Lectins used for identifying carbohydrate residues in paraffin-embedded tissue sections.

LECTIN	ACRONYM	CONCENTRATION (µl/ml)	SPECIFICITY a,b
<i>Ulex europaeus</i> agglutinin-I	UEA-I	30	α-L-Fuc
<i>Arachis hypogaea</i> agglutinin	PNA	10	β-D-Gal (β1→3) D-GalNAc
<i>Ricinus communis</i> agglutinin-I	RCA-I	30	β-Gal
<i>Glycine maxi</i> agglutinin	SBA	30	α-D-GalNAc; β-D-GalNAc
<i>Dolichos biflorus</i> agglutinin	DBA	30	α-D-GalNAc
<i>Triticum vulgaris</i> agglutinin	WGA	30	β-D-GlcNAc; NeuNAc
<i>Canavalia ensiformis</i> agglutinin	Con A	30	α-D-Man; α-D-Glc

a: Goldstein and Hayes (1978). b: Fuc, fucose; Gal, galactose; GalNAc, N-acetylgalactosamine; Glc, glucose; GlcNAc, N-acetylglucosamine; Man, mannose; NeuNAc, acetyl neuraminic acid (sialic acid).



TIFF format. After spatial and intensity of light calibration of the images, the immunohistochemically stained area and the optical density (OD) of the labelled reaction defined by the antigen-antibody complex (Wells et al., 1993) was obtained. Values registered from the histograms obtained from at least 25 images of each slide were exported to a spreadsheet in order to perform the statistical analysis.

**Table 2.** Nuclear and total surface of normal cytotrophoblastic and cytotrophoblastic-like cells.

	NUCLEAR SURFACE	TOTAL SURFACE
Cytotrophoblastic-like cells	56.9±13.2	298.2±30.8
Cytotrophoblastic cells	51.7±7.0	276.9±27.1
Significance	N/S	N/S

N/S: non significant. Numbers are expressed in  $\mu\text{m}^2$ .

### Statistical analysis

The analysis of variance was used to evaluate differences between experimental groups. Tuckey's method (Zar, 1984) was used as a post hoc test. Significant differences between the selected retrieval methods were defined as those with an error probability  $<0.05$ . Highly significant differences were defined as those with a P value  $<0.01$ .

### Results

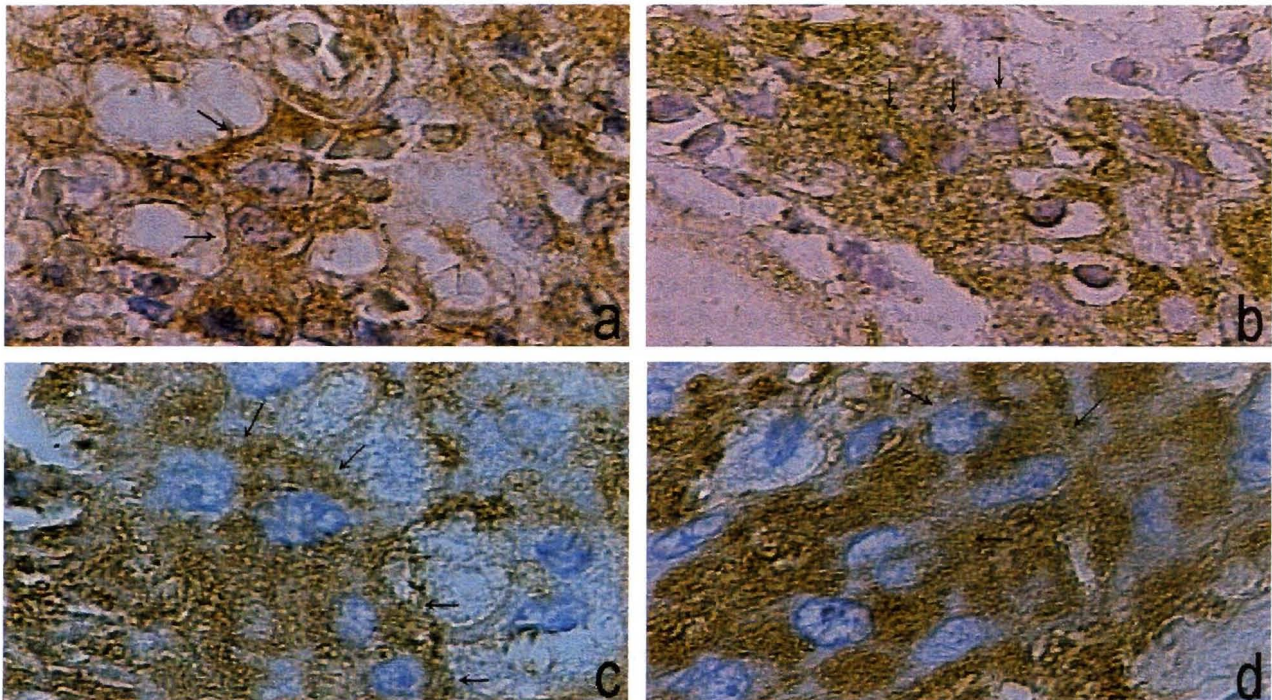
Figure 1 shows the immunohistochemical and lectinhistochemical staining of cytotrophoblastic and cytotrophoblastic-like cells.

Morphometric analysis showed that there had been non-statistically significant differences between the mean nuclear surface and between total surface of the

**Table 3.** Percentage of immunohistochemically-stained area of cytotrophoblastic cells in control cases and cytotrophoblastic-like cells in SIPS.

	CYTOTROPHOBLASTIC CELLS	CYTOTROPHOBLASTIC-LIKE CELLS	SIGNIFICANCE <sup>a</sup>
Pancytokeratin	59.43±13.00	42.86±8.19	N/S
Vimentin	1.80±0.30	2.30±0.40	N/S
Desmin	2.80±0.50	3.10±0.90	N/S

<sup>a</sup>: Significance between cytotrophoblastic and cytotrophoblastic-like cells. Numbers express the percentage of immunohistochemical stained area of the whole cell  $\pm$  SD.



**Fig. 1.** Immunohistochemical and lectinhistochemical staining of cytotrophoblastic and cytotrophoblastic-like cells. **a.** Normal placental labyrinth. Cytotrophoblastic cells positive to antipancytokeratin antibodies (arrows). **b.** Cytotrophoblastic-like cells positive to antipancytokeratin antibodies in SIPS (arrows). **c.** Binding of PNA lectin to cytotrophoblastic cells in normal placenta (arrows). **d.** PNA lectin binding to cytotrophoblastic-like cells in SIPS (arrows). x 100



cytotrophoblastic cells in normal placenta and cytotrophoblastic-like cells in SIPS (Table 2).

Table 3 shows the pancytokeratin, vimentin and desmin immunohistochemical staining percentage of normal cytotrophoblastic cells and cytotrophoblastic-like cells. Non-significant differences were observed between the three types of IF of both cells. On the contrary, highly significant differences were observed between the anti-cytokeratin staining and the other two IF in both types of cells.

Table 4 expresses the percentage of lectin-immunostained area in cytotrophoblastic and cytotrophoblastic-like cells of the seven different lectins used in this study, as well as its statistical significance. PNA and WGA lectins evidence significant differences between both cells, the stronger staining corresponding to the cytotrophoblastic-like cells. The differences between the other lectins were not significant.

## Discussion

Placenta in carnivores is zonal, belt-like, and endotheliocorial, from the point of view of Strahl's classification, and Grosser's histological classification, respectively (Michel, 1968; Björkman, 1970).

According to the morphology of its chorionic villi, the placenta of the bitch is considered labyrinthic, where the following areas can be defined: a) the chorioalantoic membrane; b) the labyrinth, with chorionic villi contacting maternal blood vessels; c) the spongy zone, which represents the fetal-maternal separation area during partum (this region corresponds to the endometrial glands, maternal blood vessels and terminal segments of the chorionic villi); d) the supraglandular layer, formed by connective tissue; and e) the deep glandular layer.

The placental labyrinth is built of three kind of cells: cytotrophoblastic cells and syncytiotrophoblastic cells of fetal origin, and decidual cells of maternal origin (Anderson, 1969). Syncytiotrophoblastic cells are multinucleated cells with dense nuclei, and have dense rough endoplasmic reticulum and Golgi vesicles and sacs. The differences between the other two cell types are mild when observed with light microscopy. The nucleus of the cytotrophoblastic cell is prominent, round or oval and the chromatin is quite homogeneously distributed, the cytoplasm contains few profiles of endoplasmic reticulum while Golgi is rarely found.

Decidual cells have extensive rough endoplasmic

reticulum. The remaining features are similar to those of the cytotrophoblastic cells when observed with light microscopy.

Although the existence of decidual cells in the bitch is under discussion, they were recognized with the help of the electron microscope (Anderson, 1969; Barrau et al., 1976). It is thought that decidual cells may prevent trophoblastic invasion (Barrau et al., 1976; Al Bassam et al., 1981) through the secretion of transforming growth factor  $\beta$  (TGF $\beta$ ) (Strickland and Richards, 1992). This peptide demonstrated the capacity of inhibiting proliferation of trophoblasts, *in vitro* (Graham and Lala, 1992; Vicóvac and Aplin, 1996).

In the last decades immunohistochemical and lectin-histochemical techniques have been used to characterise cells in the placenta of different species. The use of some specific trophoblastic markers such as chorionic gonadotrophin and placental lactogen, were not suitable for detecting trophoblastic cells in the bitch (El Etreby, 1975). Apparently, other cell markers like intermediate filaments have not been tested in the bitch, although there is abundant information in human, primate and mouse placentas (Khong et al., 1986; Blankenship et al., 1993; Blankenship and King, 1993).

Regarding cytotrophoblastic-like cells, our present data indicate the expression of cytokeratins and lack of expression of vimentin and desmin. Not only is the expression of cytokeratins in these cells coincident with the results in the normal control samples, but also in different types of trophoblastic cells present in baboon (Pijnenborg et al., 1996), macaque (Blankenship et al., 1992; Blankenship and King, 1993), and human placentas (Khong et al., 1986). The previous observations would confirm the fetal origin of the cytotrophoblastic-like cells in SIPS.

Some cells observed in our work, which have similar morphological and immunohistochemical characteristics to cytotrophoblastic cells, invade the endometrium blood vessel walls. Therefore, it is also possible to suggest a trophoblastic origin of these cells. This is in accordance with the observations of the endovascular trophoblastic cells present in higher primates. Nevertheless, the trophoblastic-like cells do not reach the lumen of the blood vessels in the bitch as occurs in primates (King and Blankenship, 1993, 1994a,b; Enders et al., 1996).

Syncytial trophoblastic-like cell groups in the miometrium of SIPS showed a slight immunoreactivity for cytokeratins, making it impossible to assert their trophoblastic origin.

**Table 4.** Comparison between lectin-histochemical binding of cytotrophoblastic and cytotrophoblastic-like cells.

	Con A	DBA	PNA	RCA	SBA	UEA	WGA
Cytotrophoblastic-like cells.	36.3 $\pm$ 3.0	28.2 $\pm$ 1.8	59.1 $\pm$ 5.2	25.0 $\pm$ 3.6	29.4 $\pm$ 2.3	34.6 $\pm$ 2.6	42.1 $\pm$ 4.2
Cytotrophoblastic cells.	38.8 $\pm$ 2.5	22.4 $\pm$ 3.0	30.2 $\pm$ 3.1	38.1 $\pm$ 1.5	48.8 $\pm$ 4.7	27.7 $\pm$ 1.7	31.4 $\pm$ 2.3
Significance	N/S	N/S	*	N/S	N/S	N/S	*

N/S: non significant; \*: significant. Numbers express the percentage of lectin-histochemical-stained area of the whole cell  $\pm$  SD.

The assumption of the trophoblastic origin of the cells present in SIPS is also confirmed by the quantitative data obtained from the morphometrical analysis of the nuclear and total surface of the cells, which resembled those found in the cytotrophoblastic cells in the normal pregnant bitch.

The establishment and sustained contact between trophoblastic cells and endometrial cells are essential for pregnancy in species with endotheliocorial placentation. These processes are likely to involve glycosylated membrane proteins, since most cell-cell adhesion occurs through carbohydrate molecules (Brandley and Schnaar, 1986). Cell adhesion molecules play a major role in embryogenesis (Edelman, 1986) including the attachment of the trophoblast to the endometrium (Richa et al., 1985). The rich carbohydrate content of cell adhesion molecules permits their general localisation within tissues by lectin binding. The demonstration of lectin binding on tissue sections involves techniques which are currently attracting the attention of many pathologists. The avidity for lectin binding is determined by the density and conformational arrangement of glycoconjugates (Spicer and Schulte, 1982).

The lectin binding profile of SIPS shown in this work coincides with that of normal cytotrophoblastic cells in the pregnant bitch except for the significant differences in the WGA and PNA staining. Sometimes, pathological conditions show alterations in the membrane carbohydrate features and consequently in their lectin binding patterns (Gabius and Gabius, 1991).

In summary, based on the results obtained so far, we suggest the trophoblastic origin of the cells found in bitches with SIPS. This is supported by the morphometrical analysis and the IF expression.

**Acknowledgements.** The authors wish to thank Mrs. Rosa Villegas de Guidi for her skillful technical assistance and Ms. Adela Heras for the proof-reading of the manuscript. Our gratitude to Dr. Maria Cecilia Castellano for the accurate clinical diagnostics and to Dr. Julio Roberto Idiart for the histopathological diagnostics. This study was partially supported by grants from CONICET (National Scientific Research Council) and from the Secretariat for Science and Technology, National University of La Plata. EJG and ELP are Research Career Members of CONICET. PEF is a fellow from the Scientific Research Commission (CIC) of the Province of Buenos Aires.

## References

- Al-Bassam M.A., Thompson R.G. and O'Donnell L. (1981). Involution abnormalities in the postpartum uterus of the bitch. *Vet. Pathol.* 18, 208-218.
- Alberts B., Bray D., Lewis J., Raff M., Roberts K. and Watson J.D. (1994). The cytoskeleton. In: *Molecular biology of the cell*. Third Edition. Garland Publishing, Inc. New York and London. pp. 788-841.
- Anderson J.W. (1969). Ultrastructure of the placenta and fetal membranes of the dog I. The placental labyrinth. *Anat. Rec.* 165, 15-36.
- Anderton B.H. (1981). Intermediate filaments: a family of homologous structures. *J. Muscle Res. Cell. Motil.* 2, 141-166.
- Barrau M.D., Abel J.H. Jr., Torbit C.A. and Tietz W.J. Jr. (1976). Development of the implantation chamber in the pregnant bitch. *Am. J. Anat.* 143, 115-130.
- Björkman N. (1970). *An Atlas of placental fine structure*. Bailliere Tindall and Cassell. London. First edition.
- Blankenship T.N., Enders A.C. and King B.F. (1993). Trophoblastic invasion and the development of uteroplacental arteries in the macaque: immunohistochemical localization of cytokeratins, desmin, type IV collagen, laminin and fibronectin. *Cell Tissue Res.* 272, 227-236.
- Blankenship T.N. and King B.F. (1993). Developmental changes in the cell columns and trophoblastic shell of the macaque placenta: an immunohistochemical study localizing type IV collagen, laminin, fibronectin and cytokeratins. *Cell Tissue Res.* 274, 457-466.
- Blankenship T.N., Enders A.C. and King B.F. (1992). Distribution of laminin, type IV collagen, and fibronectin in the cell columns and trophoblastic shell of early macaque placentas. *Cell. Tissue Res.* 270, 241-248.
- Brandley B.K. and Schnaar R.L. (1986). Cell-surface carbohydrates in cell recognition and response. *J. Leukocyte Biol.* 40, 97-111.
- Burke T.J. (1977). Postparturient problems in the bitch. *Vet. Clin. North Am.* 7, 693-698.
- Castellano M.C., Gimeno E.J. and Idiart J.R. (1982). Subinvolución de los sitios de inserción placentaria en la perra. *Gaceta Vet.* 44, 639-646.
- Edelman G.M. (1986). Cell adhesion molecules in the regulation of animal form and tissue pattern. *Annu. Rev. Cell. Biol.* 2, 81-116.
- El Etreby M.F. (1975). Immunohistological localisation of antigens related to human chorionic gonadotropin and human placental lactogen in the uterus of pregnant beagle dogs. *Acta Endocrinol.* 79, 157-163.
- Enders A.C., Lantz K.C. and Schlafke S. (1996). Preference of invasive cytotrophoblast for maternal vessels in early implantation in the Macaque. *Acta Anat.* 155, 145-162.
- Gabius H.J. and Gabius S. (1991). Tumour lectinology: A glycobiological approach to tumour diagnosis and therapy. *Lectin Rev.* 1, 91-102.
- Gimeno E.J., Massone A.R., Marino F.P. and Idiart J.R. (1995). Intermediate filament expression and lectin histochemical features of canine transmissible venereal tumour. *APMIS* 103, 645-650.
- Goldstein I.J. and Hayes C.E. (1978). The lectins: carbohydrate binding proteins of plants and animals. *Adv. Carbohydr. Chem. Biochem.* 35, 127-340.
- Graham C.H. and Lala P.K. (1992). Mechanisms of placental invasion of the uterus and their control. *Biochem. Cell Biol.* 70, 867-874.
- Hsu S. M. and Ree H. J. (1983). Histochemical studies on lectin binding in reactive lymphoid tissues. *J. Histochem. Cytochem.* 31, 538-546.
- Khong T.Y., Lane E.B. and Robertson W.B. (1986). An immunocytochemical study of fetal cells at the maternal-placental interface using monoclonal antibodies to keratins, vimentin and desmin. *Cell Tissue Res.* 246, 189-195.
- King B.F. and Blankenship T.N. (1993). Development and organization of primate trophoblast cells. In: *Trophoblast cells. Pathways for maternal-embryonic communication*. Soares M.J., Handwerger S. and Talamantes F. (eds). Springer-Verlag, New York, Inc. pp 13-30.
- King B.F. and Blankenship T.N. (1994 a). Differentiation of the chorionic plate of the placenta: cellular and extracellular matrix changes during development in the macaque. *Anat. Rec.* 240, 267-276.

*Cytotrophoblastic-like cells in SIPS*

- King B.F. and Blankenship T. N. (1994b). Ultrastructure and development of a thick basement membrane-like layer in the anchoring villi of macaque placentas. *Anat. Rec.* 238, 498-506.
- Laitinen L., Virtanen I. and Saxen L. (1987). Changes in the glycosylation pattern during embryonic development of mouse kidney as revealed with lectin conjugates. *J. Histochem. Cytochem.* 35, 55-65.
- Michel G. (1968). *Kompndiumj der Veterinar-Anatomie. Band VI: Embryologie.* First Edition. Veb Gustav Fisher Verlag. Jena Alemanie.
- Pijnenborg R., Hooghe T.D. , Vercruysse L. and Bamba C. (1996). Evaluation of trophoblast invasion in placental bed biopsies of the baboon, with immunohistochemical localisation of cytokeratin, fibronectin and laminin. *J. Med. Primatol.* 25, 272-281.
- Ramaekers F., Broers J. and Vooijs G. (1986). Immunocytochemistry of intermediate filament proteins. In: *Immunocytochemistry: modern methods and applications.* Polak J.M. and Van Noorden S. (eds). 'P.S.G. Wright. Boston. pp 390-400.
- Richa J., Damsky C.H., Buck A., Knowles B.B. and Solter D. (1985). Cell surface glycoproteins mediate compaction, trophoblast attachment, and endoderm formation during early mouse development. *Dev. Biol.* 108, 513-521.
- Schall W.D., Duncan J.R., Finco D.R. and Knecht C.D. (1971). Spontaneous recovery after subinvolution of placental sites in a bitch. *J. Am. Vet. Med. Assoc.* 159, 1780-1782.
- Spicer S.S. and Schulte B.A. (1982). Identification of cell surface constituents. *Lab. Invest.* 47, 2-4.
- Strickland S. and Richards W.G. (1992). Invasion of the Trophoblasts. *Cell* 71, 355-357.
- Vicövac L. and Aplin J.D. (1996). Epithelial-mesenchymal transition during trophoblast differentiation. *Acta Anat.* 156, 202-216.
- Wells W.A., Rainer R.O. and Memoli V.A. (1993). Equipment, standardization, and application of image processing. *Am. J. Clin. Pathol.* 99, 48-56.
- Zar J.H. (1984). Multiple comparisons. In: *Biostatistical analysis.* Englewood Cliffs Eds. Prentice Hall. N.Y.J. pp 185 205.

Accepted April 20, 1998